

Pia K. Schuler<sup>a</sup>, Christian M. Matter<sup>a</sup>,  
Andreas Künzli<sup>b</sup>, Thomas F. Lüscher<sup>a</sup>

<sup>a</sup> Cardiovascular Research, Institute of Physiology, Zurich  
University and Cardiology, CardioVascular Center,  
UniversityHospital Zurich, Switzerland

<sup>b</sup> Cardiac Surgery, UniversityHospital Zurich,  
Switzerland

## Migration of fractured sternal wires after CABG in a smoker

### Case report

A 74-year-old white male smoker with chronic obstructive pulmonary disease and marked coughing experienced a transmural, anterior myocardial infarction two years prior to the current visit. Because of postinfarction angina, he underwent elective coronary artery bypass grafting including the use of the left internal mammary artery at our institution (fig. 1a). His postoperative course was complicated by persistent smoking and coughing. Three months after operation, he presented to our outpatient clinic with cough-induced pain at the proximal end of the sternum. The thoracic X-ray showed fracture of the proximal sternal

wire (fig. 1b). One and a half year later, the patient presented again with pain on coughing and moving, now expanding all over his sternum. He experienced no pain with normal breathing. His physical examination revealed a median thoracic scar without signs of inflammation nor palpable wires, but abnormal sternal mobility with cracking. The thoracic X-ray showed fracture of all sternal wires (fig. 1c). In addition, fractured parts of the proximal wire have migrated at the dorsal side of the sternum from its proximal to its distal end. A conservative management with regular controls was chosen given the minor complaints of the patient. The decision against reoperation based on the increased risk of injuring the bypasses (in particular the mammary graft to the left anterior descending coronary artery), the likelihood of postoperative infection as well as recurrence of postoperative pseudoarthrosis given the patient's ongoing smoking and coughing.

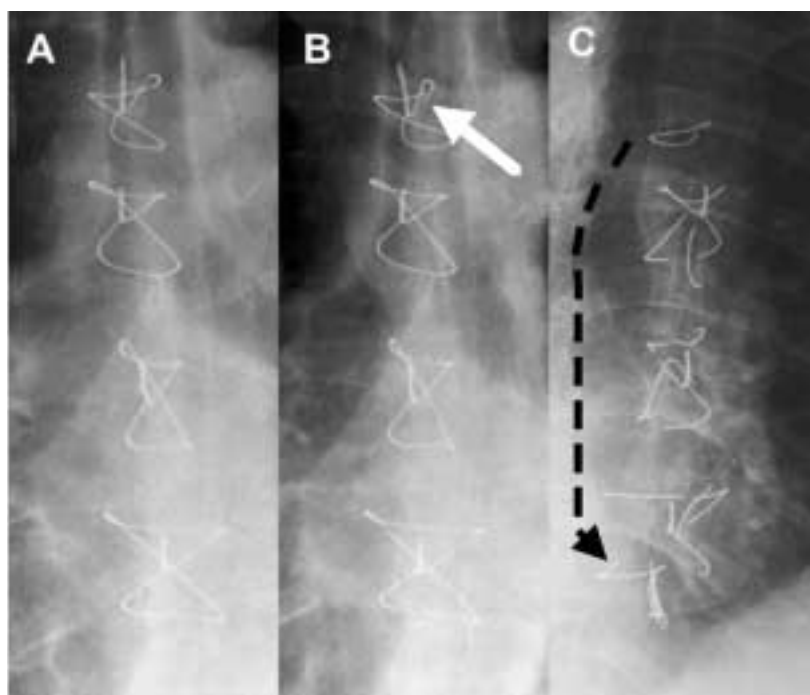
### Figure 1

Series of conventional X-rays of sternum:

A. Shortly after coronary artery bypass operation; note the intact sternal wires.

B. Three months post surgery; breaking of the proximal sternal wire (white arrow) caused by coughing.

C. 1½ years later; complete breaking of all sternal wires and distal migration of wire particles (black arrow) causing pain on coughing and movements of the patient.



Correspondence:  
Thomas F. Lüscher, MD  
Professor and Head of Cardiology  
CardioVascular Center  
UniversityHospital Zurich  
Rämistrasse 100  
CH-8091 Zurich  
E-Mail: cardiotfl@gmx.ch