

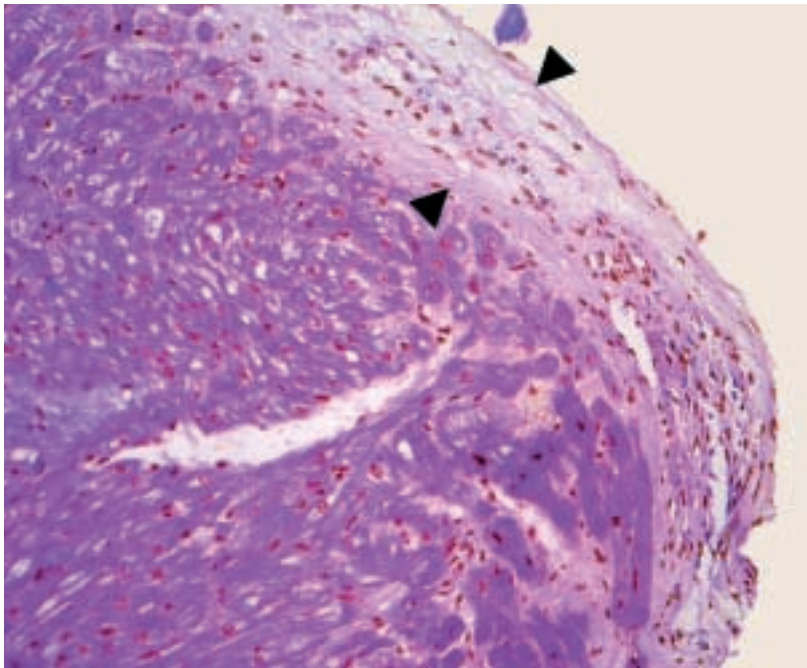Figure 2

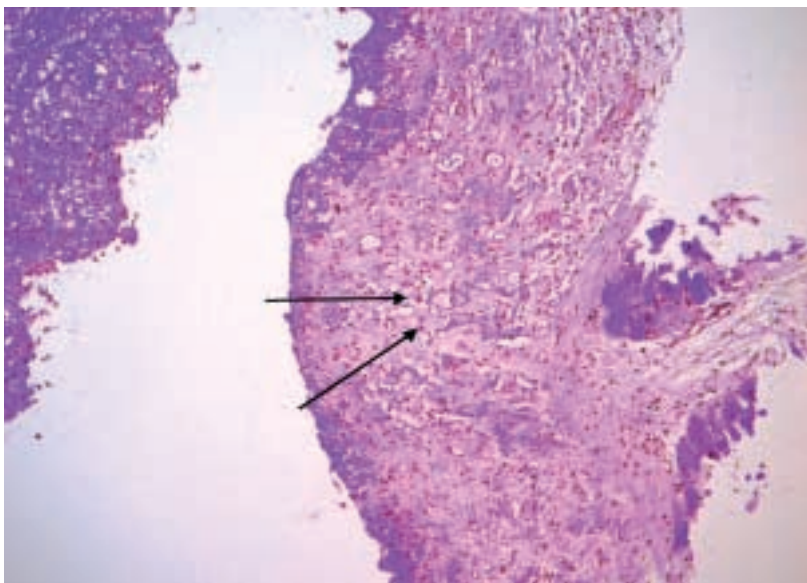


Figure 3

syndrome or so-called idiopathic hyper-eosinophilic syndrome [2, 3]. Magnetic resonance imaging showed multiple little cerebral infarctions probably due to embolism from thrombotic material in the left ventricle [3, 4].

References

- 1 Acquatella H, Schiller NB. Echocardiographic recognition of Chagas' disease and endomyocardial fibrosis. *J Am Soc Echocardiogr* 1988;1:60–8.
- 2 Desreumaux P, Janin A, Dubucquoi S, et al. Synthesis of interleukin-5 by activated eosinophils in patients with eosinophilic heart diseases. *Blood* 1993;82:1553–60.
- 3 Weller PF, Bubley GJ. The idiopathic hypereosinophilic syndrome. *Blood* 1994;83:2759–63.
- 4 Chusid MJ, Dale DC, West BC, et al. The hypereosinophilic syndrome: analysis of fourteen cases with review of the literature. *Medicine (Baltimore)* 1975;54:1–27.