

Marcello Di Valentino, Rolf Wytttenbach,  
Mario Alerci, Jeanne-Marie Segatto,  
Felix Mahler, Guido Mariotti, Augusto Gallino

Department of Cardiology and Radiology,  
Ospedale San Giovanni,  
Bellinzona,  
Switzerland

## Subclavian and axillary giant cell arteritis after influenza vaccine

### Case report

A 64-years-old women with history of rheumatic polymyalgia 11 years before developed sub-acute bilateral claudicatio at both arms few days after injection of influenza vaccine (Fluvarix®). At clinical examination both arterial radialis pulses were absent. Arterial blood pressure was 110/80 mm Hg at the right arm and not measurable at the left arm. Arterial blood pressure measured by Doppler ultrasonography at both ankle was 150 mm Hg. A systolic arterial murmur was heard at the level of the proximal subclavian artery. Erythrocyte rate sedimentation was 61 mm/h. Duplex sonography showed suspicion of arterial occlusions of the upper extremity arteries. Angio-magnetic-resonance showed occlusion

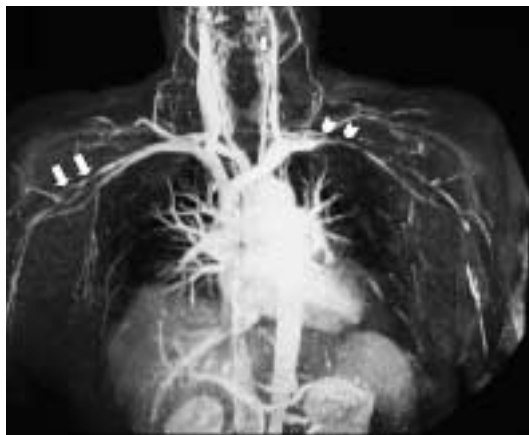
of the right axillar-brachial artery portion (length 4 cm) (fig. 1: arrows), and an occlusion of the left subclavian artery (fig. 1: arrow-heads). The clinical diagnosis of giant cell arteritis was made and therapy with prednisone (50 mg/day) was initiated. Given the temporal association with previous vaccination, HLA typing was performed and the patient was identified as HLA-DRB1\*04.

### Discussion

This short case shows a rare complication of influenza vaccine. Giant cell arteritis is a chronic vasculitis of large and medium sized vessels and involves the cranial branches of the arteries originating from the aortic arch and in approximately 10 to 15 percent of patients the subclavian and axillary arteries [1]. The giant cell arteritis may be triggered by vaccine influenza especially in patient positive for HLA-DRB1\*04. Patients with this HLA phenotype have genetic susceptibility to develop giant cell arteritis [2].

**Figure 1**

MRI shows the occlusion of the right axillar-brachial (arrows) and an occlusion of the left subclavian artery (arrow-heads).



### References

- 1 Klein RG, Hunder GG, Stanson AW, Sheps SG. Large artery involvement in giant cell (temporal) arteritis. *Ann Intern Med* 1975;83:806–12.
- 2 Perez C, Loza E, Tinture T. Giant cell arteritis after influenza vaccine. *Arch Intern Med* 2000;160:2677.

Correspondence:  
Prof. Augusto Gallino  
Cardiologia, Angiologia e Medicina Interna  
Ospedale San Giovanni  
CH-6500 Bellinzona  
E-Mail: agallino@bluewin.ch