

Silvia Ulrich^{a, b}, Manuel Fischler^a,
Rudolf Speich^{a, b}

^a Department of Internal Medicine,
University Hospital, Zurich, Switzerland

^b Department of Pulmonology,
University Hospital,
Zurich, Switzerland

Current and future therapies for pulmonary hypertension¹

Summary

The diagnosis of pulmonary hypertension (PH) is often difficult and many different disorders may lead to an elevated pulmonary arterial pressure necessitating therapy. Untreated PH usually has a dismal prognosis due to an progressive increase in pulmonary vascular resistance leading to right ventricular failure and death. Beside conservative therapeutic strategies, such as anticoagulation and diuretics, the past decade has brought remarkable improvements in the therapy for the major classifications groups of PH (pulmonary arterial and chronic thromboembolic pulmonary hypertension) based on a better understanding of the underlying pathobiology. The selection of appropriate therapies for PH remains complex, requires familiarity with the disease process, evidence from clinical trials, complicated drug delivery systems, dosing regimens, side effects and complications. Despite these advances, neither of the current therapeutic pathways is curative. This article discusses the medication classes currently available in the treatment of PH, the role of combination therapy and the surgical option for some patients with chronic thromboembolic disease. The review will close with speculations on new directions emerging from bench research with a potential for future valuable therapies in this life-threatening disease.

Key words: pulmonary hypertension; pulmonary arterial hypertension; chronic thromboembolic pulmonary hypertension; therapy

Zusammenfassung

Die pulmonale Hypertonie (PH) führt anfänglich zu wenigen unspezifischen Beschwerden und wird daher oft verspätet diagnostiziert, und unterschiedliche Krankheiten können sekundär zur PH führen. Eine unbehandelte PH führt zu progressivem Ansteigen des Gefässwiderstandes im Lungenkreislauf mit konsekutiver Rechtsherzbelastung und schlechter

Prognose. Neben herkömmlichen Therapien wie oraler Antikoagulation und Diuretika brachten einige in den letzten Jahren aus Erkenntnissen der Pathophysiologie entwickelte neue Medikamente erhebliche Fortschritte in der Behandlung der häufigsten Formen der PH wie pulmonal-arterieller Hypertonie (PAH) und chronisch-thromboembolischer PH (CTEPH). Die Wahl der geeigneten Therapie bei PH bleibt jedoch komplex und benötigt eingehende Kenntnisse der Krankheitsentstehung, der Evidenz von klinischen Studien und der zum Teil komplizierten Verabreichungs- und Dosierungsformen sowie der Nebenwirkungen der Medikamente. Trotz der Fortschritte ist keine der neueren Therapien kurativ. Dieser Artikel diskutiert die verschiedenen für PH zugelassenen Medikamentenklassen, die Rolle der Kombinationstherapie und die chirurgischen Optionen für Untergruppen von Patienten, insbesondere mit CTEPH. Zum Schluss werden, basierend auf Erkenntnissen der Grundlagenforschung, mögliche neue Angriffspunkte mit einem Potential für zukünftige Therapien für diese lebensbedrohliche Krankheit aufgezeigt.

Schlüsselwörter: pulmonale Hypertonie; pulmonal-arterielle Hypertonie; chronisch-thromboembolische pulmonale Hypertonie; Therapie

Introduction

The diagnosis of pulmonary hypertension (PH) is often difficult and many different disorders may lead to an elevated pulmonary arterial pressure necessitating therapy [1]. Until re-

¹ Dieser Beitrag erschien bereits in leicht abgeänderter Form in Swiss Med Wkly. 2007;137:73–82.

Conflict disclosures of interest. All the authors have been invited for attending conferences by Actelion, Switzerland and Shering, Switzerland. SU and RS have received research grants from Actelion, Switzerland. RS has received research grants from Roche/Switzerland and support for a study nurse from Actelion, Switzerland and Shering, Switzerland.

Correspondence:
Silvia Ulrich, MD
Department of Internal Medicine
Raemistrasse 100
CH-8005 Zurich
Switzerland
E-Mail: silvia.ulrich@usz.ch

cently, most classifications of pulmonary hypertensive diseases had a very poor prognosis due to progressive increase in pulmonary vascular resistance and consecutive right heart failure in lack of a specific therapy [2]. In the past decade however, advances in the pathobiological understanding resulted in newer therapeutic concepts which lead to considerable improvement of exercise capacity, quality of life and survival (fig. 1) [3]. The current article focuses on the current medical therapy in pulmonary arterial hypertension (PAH) (summarised in table 1 and 2), the surgical option and medical alternative in chronic thromboembolic pulmonary hypertension (CTEPH) and closes with new directions emerging from bench research with a potential for future valuable therapies in this life-threatening disease.

Conventional therapy

All patients with PH should avoid excessive exercise that may cause dyspnoea or dizzy spell. Hot weather and especially hot showers are potentially dangerous in these patients. Similarly hypoxaemia, volume overload and infections should be avoided or promptly treated. Patients should prefer smaller meals with low salt content. Expert advice for sojourns at high altitude and air travels is recommended. General and spinal anaesthesia both are associated with increased perioperative risk and should be avoided or planned carefully. Since pregnancy carries a very high risk of morbidity and mortality, strict con-

traception is important. Oestrogen-containing preparations should be avoided.

Anticoagulation

Oral anticoagulation with vitamin K antagonists is indicated for all patients with CTEPH, idiopathic and familial PAH based on prospective cohort studies that showed improvement in survival in anticoagulated patients [4–6]. The indication is less clear for other forms of PH. Most experts agree with the concept of oral anticoagulation in all patients with PH in the absence of contraindications. Secondary thrombotic occlusions of peripheral pulmonary vessels may be prevented with oral anticoagulation [6, 7] although no prospective trials are available to confirm this hypothesis. Similarly, no prospective clinical trials are available addressing a possible benefit of aspirin and other inhibitors of platelet aggregation. Based on short time pharmacological assessments, there might be a benefit [8].

Diuretics

Diuretic therapy (mainly loop diuretics and spironolactones) is successfully utilised in most PH-patients for the treatment of right heart failure.

Other drugs for left heart failure

There are only small prospective trials available concerning the use of angiotensin converting enzyme inhibitors (ACEI), angiotensin II receptor blockers and digoxin in pulmonary arterial hypertension [9, 10]. For neither medication a clear benefit nor harm was demonstrated. Thus, their use will depend on clinical judgment and concomitant morbidities. Although PH seems to be accompanied by sympathetic activation [11], the use of beta receptor blockers in analogy to their benefit in left heart failure, is discouraged in PH by most experts to date, mainly due to their negative inotropic potential and a demonstrated deleterious effect in portopulmonary hypertension [12].

Long-term oxygen therapy

Long-term continuous oxygen therapy has been proven to improve survival and pulmonary haemodynamics in hypoxaemic patients with chronic obstructive pulmonary disease [13–17]. Several small studies which included patients with various classifications of PH showed short-term improve of pulmonary haemodynamics with oxygen therapy [13, 16, 18–21]. Based on these results, long-term continuous oxygen therapy is recommended for all

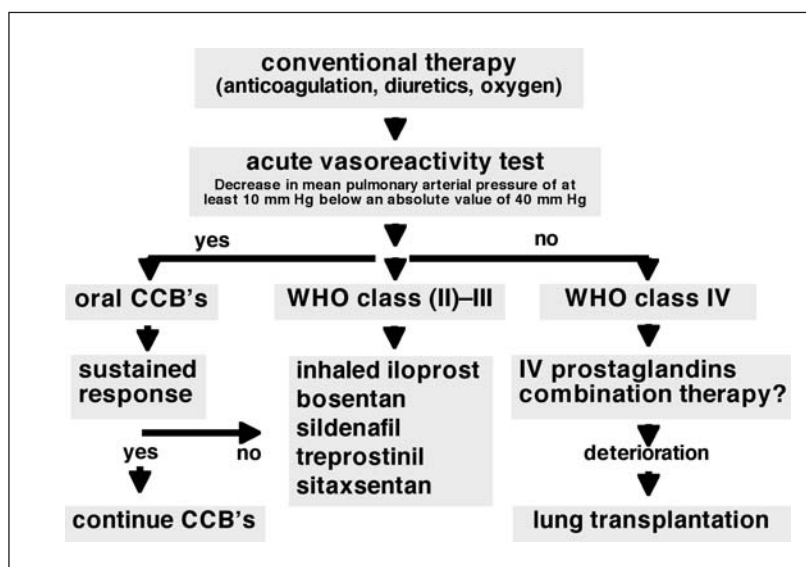


Figure 1
Treatment algorithm for pulmonary arterial hypertension.

hypoxaemic PH patients (PaO₂ <8 kPa) with the following conditions: electrocardiographic evidence of right heart failure, oedema due to congestive heart failure, and erythrocythaemia with a haematocrit greater than 56% [22]. Supplemental oxygen should be administered to increase the oxygen saturation to 90% [13].

Calcium-channel blocker therapy

The rationale for high dose calcium-channel blocker (CCB) therapy in IPAH dates back to the early nineties, where Rich and colleagues could demonstrate a survival benefit in patients with PAH who decreased their pulmonary vascular resistance during an acute vasoreactivity test at least by 20% [4]. Recently, the indication for CCB in IPAH was further clarified by a retrospective review including 557 patients. Herein, a one-year sustained response to CCB therapy was only found in the subgroup of patients, who decreased their mean pulmonary arterial pressure ≥10 mm Hg below an absolute value of 40 mm Hg [23, 24]. Only 10% respond initially to CCB, and only half of them show a sustained response after one year of treatment [23].

If this algorithm for the use of CCB can be extrapolated to other classifications of PH remains unknown in lack of according studies.

Current specific therapy for PAH

Prostanoids

Prostacyclin is the main metabolite of arachidonic acid produced in the vascular endothelium. Prostacyclin induces relaxation of vascular smooth muscle cells by increasing the production of cyclic adenosine monophosphate, it also inhibits the growth of smooth muscle cells in vitro and is a powerful inhibitor of platelet aggregation (fig. 2 and 3). The value of continuous intravenous epoprostenol in patients with idiopathic and scleroderma-associated pulmonary arterial hypertension to improve exercise capacity, functional class and survival (in IPAH) has been documented in two randomised controlled trials (RCT) [24–26]. Continuous intravenous epoprostenol was the first prostanoid available and still is considered the first-line therapy for NYHA class IV patients [24, 27]. More recently, the efficacy of continuous subcutaneous treprostinil was demonstrated [28]. However, the administration of both of these medications makes their clinical

Table 1
Treatment of pulmonary arterial hypertension

Medication	application	indication	grading of evidence	recommendation
Anticoagulation	oral		C	I
Diuretics	oral		–	II
Oxygen	inhaled	PaO ₂ <8 kPa	–	I
High dose CCB	oral	IPAH / FPAH	C	I *
Iloprost	inhaled	IPAH III	A	I
Iloprost	intravenous	others	C	II
Bosentan	oral	PAH III	A	I
Treprostinil	subcutaneous	IPAH III	B	II
Sildenafil	oral	PAH III	A	I
Lung transplantation	surgery		C	I
Atrial septostomy	surgery		C	II

Grading of evidence:

A = data derived from multiple RCT's; B = data derived from a single RCT or from multiple RCT's with heterogeneous results; C = data derived from small non RCT and/or consensus opinion of experts

Recommendation: I = strong; II = predominant

* Only if a positive acute response to vasodilators is noted ("responder")

Table 2
Summary of therapeutic approaches for pulmonary hypertension.

Site of action	classes of agents
Anticoagulant therapies	coumarins
Inhalation therapies	oxygen, prostacyclin analogues, nitric oxide donors
Vasodilator therapies	oxygen, calcium channel blockers, endothelin receptor antagonists
Vasodilator and anti-platelet therapies	prostacyclin analogues, nitric oxide donors, phosphodiesterase inhibitors
Anti-inflammatory therapies	prostacyclin analogues, nitric oxide donors, endothelin receptor antagonists, statins
Anti-remodelling therapies	nitric oxide donors, endothelin receptor antagonists

use rather unattractive. Iloprost is a chemically stable prostacyclin analog that can be delivered via inhalation [29]. In a randomised controlled, multicentre trial including patients with IPAH, PAH associated with connective tissue disease and CTEPH a favorable effect of inhaled iloprost on exercise capacity, NYHA functional class and pulmonary haemodynamics was shown [30]. Due to its proven efficacy, simple application and pulmonary selectivity, inhaled iloprost is considered as first-line prostanoid by several experts for moderately to severe ill patients with PAH and CTEPH. Current dosing recommendations advise at least six inhalations each day with a special ultrasound-based nebuliser requiring 5–10 minutes per inhalation to reach a daily dosage of 100 to 150 µg. This mandates professional instruction by pulmonary hypertension nurse. Inhalation therapy is generally well tolerated; the most frequent adverse events include headache, cough and flushing pronounced shortly after inhalation.

Endothelin receptor antagonists

Endothelin-1 (ET-1) is a potent endogenous vasoconstrictor and smooth muscle cell mitogen that may contribute to pulmonary vascular hypertrophy associated with PAH (fig. 2 and 3) [31, 32]. ET-1 is over expressed in plasma and lung tissue of patients with IPAH and scleroderma-associated PAH [33, 34]. The action of ET-1 is mediated by two receptors, ET_A and ET_B. Activation of ET_A facilitates vasoconstriction and proliferation of vascular smooth muscle cells, whereas ET_B receptors are thought to be involved in the clearance of endothelin. Activation of ET_B receptors may also cause vasodilation and NO release [35]. Whether it is preferable to block both ET_A and

ET_B receptors or to target only ET_A is currently debated [24]. A favourable effect of bosentan, a dual (ET_A and ET_B) receptor antagonist, on exercise capacity and cardiopulmonary haemodynamics was shown in two double-blind, randomised controlled multicentre trials in patients with moderate to severe PAH [33, 34]. The trial regimens of 125 mg twice daily and 250 mg twice daily both were effective. Although the treatment effect was more pronounced for the 250 mg bid dosage, the difference was not significant. Therefore, the currently recommended bosentan dose is 125 mg bid. Adverse events which might be encountered are headache, hypotension, limb oedema, hepatitis, increased varicosities and flush. Although the elevation in hepatic aminotransferases is dose-dependent, mostly asymptomatic and reversible, monthly liver function tests are recommended for all patients on bosentan therapy. Other potential toxicities of bosentan include mild anaemia, testicular atrophy and teratogenicity requiring regular haemoglobin testing. Careful attention to the use of adequate contraception in women of childbearing age is warranted. Importantly, bosentan may decrease the efficacy of hormonal contraceptives.

Phosphodiesterase inhibitors

Increased cellular levels of cyclic guanosine monophosphate result in vasodilatation from relaxing vascular smooth muscle cells (fig. 2 and 3). Cyclic guanosine monophosphate is degraded by phosphodiesterase (PDE). Inhibition of PDE by inhibitors (PDE-I) therefore promote vasodilatation. The main PDE isoform in the lung vasculature is PDE-5. Sildenafil, a potent and specific inhibitor of PDE-5, has been shown to decrease the mean pulmonary arterial pressure and vascular resistance while increasing the cardiac index in patients with PAH [36, 37]. The long-term effect of sildenafil has been recently addressed in a large multicentre, randomised, placebo-controlled, double-blinded trial (SUPER-1) which randomised 278 patients during 12 weeks to either placebo, 20, 40 or 80 mg of sildenafil three times per day. The trial included patients with NYHA class II, III and IV (39, 58 and 3%) of whom 63% had idiopathic PAH, 30% PAH related to connective tissue disease, and 7% had congenital heart disease. There was significant improvement in both 6-minute walking distance and pulmonary haemodynamics in all treatment groups with a trend towards greater efficacy with the highest dose. A sustained positive effect of sildenafil after one

Figure 2
Vasoactive mediators in pulmonary hypertension.

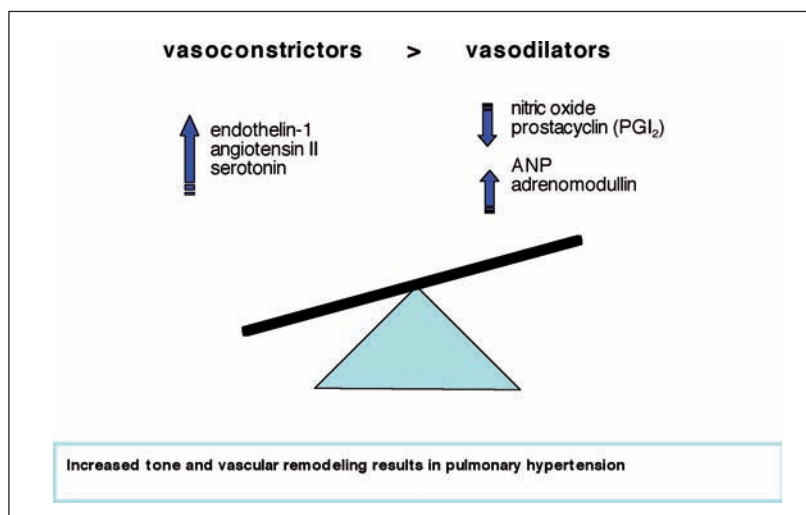
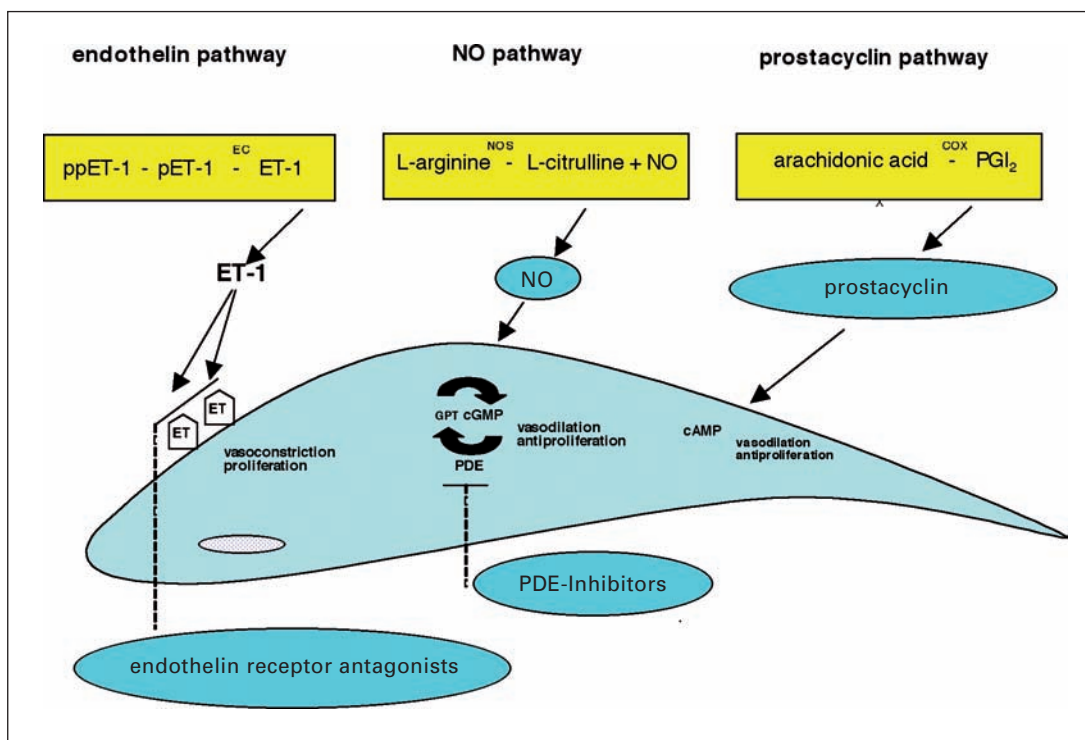


Figure 3

Major pathways for the maintenance of the tone and structure of the endothelium.

NO = nitric oxide; ECE = Endothelin converting enzyme; NOS = NO synthases; COX = cyclo-oxygenase; cGMP = cyclic guanylate monophosphate; GTP = guanosin triphosphate; PGI₂ = prostacyclin; PDE = phosphodiesterase; cAMP = cyclic adenosine monophosphate; ET-1 = endothelin-1; ETA = endothelin A receptor; ppET-1 = preproendothelin-1; pET-1 = proendothelin-1



year was seen in 230 patients who were up-titrated to 80 mg of sildenafil three times daily.

The American Food and Drug Administration (FDA) and the European Medicines Agency (EMA) approved sildenafil for the treatment of PAH NYHA class III and recommend a dose of 20 mg three times a day.

Side effects are mostly mild to moderate and include headache, epistaxis, nasal congestion, visual disturbances, lower leg oedemas, cardiac arrhythmias. No cases of priapism were noted in the controlled trials. Although other PDE-I (vardenafil, tadalafil) share similar properties in the treatment of erectile dysfunction, no RCT exists concerning their long-term efficacy in PH. However, efficacy on haemodynamics and oxygenation appears to differ considerably between the newer agents [38]. At the moment, these agents are not yet recommended for the treatment of PH.

Combination therapy

With the development of the above mentioned therapeutic strategies that confer different mechanism of actions, considerable interest has emerged regarding combination therapy, in analogy to strategies utilised in the treatment of left heart failure, systemic hypertension and many forms of cancer. Some agents, such as PDE-I, might enhance and prolong the effects of others, like the prostanoids. Other combinations might simply approach the problem of PAH from different mechanistic angles, and therefore have at least partially ad-

ditive effects. Such combinations not only offer the possibility of enhanced efficacy, but also may permit individual agents to be used in lower dosages, thereby minimising toxicity. On the other hand, it is also possible that combination therapy could result in drug-drug interactions, with unexpected increases in toxicity. Several small, mostly open-label, or uncontrolled trials and prospective observational studies have already demonstrated a favourable effect of combination therapy [39–46]. The only randomised trial of bosentan plus continuous intravenous epoprostenol (BREATHE-2) did not show a significant improvement, possibly due to the relatively small number of enrolled patients. Larger, multicentre, randomised controlled trials are ongoing and investigate the efficacy, safety and interaction of vasodilator and antiproliferative combination therapy in PAH. By all means, combination therapy in PAH is, albeit presumably efficient and beneficial for many patients, costly and difficult to manage. This form of therapy should be managed by experienced tertiary care centres only.

Therapy for chronic thromboembolic pulmonary hypertension

CTEPH is one of the leading causes of severe pulmonary hypertension. The disease is notoriously under diagnosed and its true preva-

lence remains unclear [5, 47]. Recently, it has been shown that at around 4% of patients with acute pulmonary embolism develop CTEPH during the following two years [5]. CTEPH is characterised by intraluminal thrombus organisation and fibrous stenosis or complete obliteration of pulmonary arteries [48]. The consequence is an increased pulmonary vascular resistance resulting in pulmonary hypertension and progressive right heart failure. Recent research suggests that the mechanistic view of CTEPH as a disease caused solely by obliteration of central pulmonary arteries due to organised thrombi may have been too simplistic [49]. Although pulmonary embolism, either as a single episode or a recurrent phenomena, is still thought to be the initiating event in many patients. However, the mechanisms of progressive pulmonary vascular remodelling are still poorly understood. Thus, treatment of CTEPH often requires a multidisciplinary approach, and beside oral anticoagulation may involve surgery, medical treatment or both.

Surgery

The treatment of choice in symptomatic patients with CTEPH is pulmonary endarterectomy (PEA) [48, 50, 51]. The operation mandates cardiopulmonary bypass and deep hypothermia between 18 and 20 °C. Endarterectomy is performed during complete circulatory arrest to avoid bleeding from systemic-to-pulmonary collaterals. The surgeon establishes the correct endarterectomy plane, which is followed down to lobar, segmental, or even subsegmental branches of each lobe. If performed in experienced centres and in carefully selected patients, PEA provides remarkable results with a periprocedural mortality rate of 5%, nearly normalised haemodynamics and substantial improvement in clinical symptoms [50, 52]. Postoperative residual pulmonary hypertension and increased pulmonary vascular resistance have been identified as the most important predictor of death [50]. These data suggest that technical operability must not necessarily confer a benefit to every patient with CTEPH, and PEA should therefore be reserved for patients with a predicted postoperative decrease in pulmonary vascular resistance of at least 50%, assessed by a multidisciplinary team [53].

Medical and interventional therapy for CTEPH

Although there is no doubt that eligible CTEPH patients should undergo PEA, it is

still uncertain how to best approach patients without surgically accessible disease. Medical therapy is now being studied in CTEPH on the basis of a pathophysiological background. Intravenous epoprostenol has been used with favourable results to achieve haemodynamic stabilisation before surgery [54–56]. Uncontrolled studies suggest a potential role of bosentan and sildenafil for inoperable CTEPH [57–59]. The only controlled trial thus far to include CTEPH patients was the Aerosolized Iloprost Randomization (AIR) study, but subgroup analyses of the 57 patients with CTEPH failed to show a significant benefit of inhaled iloprost on haemodynamics or exercise capacity. A randomised, placebo controlled trial is currently under way to determine the safety and efficacy of bosentan in patients with inoperable CTEPH.

Another approach in surgically inaccessible patients with CTEPH is balloon pulmonary angioplasty. Case reports and series already demonstrated favourable effects of balloon pulmonary angioplasty performed by experienced hands on pulmonary haemodynamics and exercise capacity in selected patients with CTEPH [60, 61].

Lung transplantation in pulmonary hypertension

Despite recent therapeutic advances for pulmonary hypertension, lung transplantation remains an important treatment option for end-stage disease. First undertaken in 1982, transplantation is the only curative therapy for IPAH. Indication for transplantation include NYHA class III/IV despite optimal medical treatment, cardiac index lower than $2 \text{ L} \times \text{min}^{-1} \text{m}^{-2}$ and a right atrial pressure greater than 15 mm Hg [62]. Whereas early mortality is slightly increased due to the required adaptive cardiopulmonary haemodynamic, patients with PH undergoing lung transplantation have similar long-term outcomes compared to other lung diseases with dramatic improvement of both quality of life and physiologic aspects [63]. One exception is the development of obliterative bronchiolitis (chronic rejection) which occurs earlier and more frequently in patients given transplantation for IPAH than other diseases [62]. Early referral to an experienced lung transplantation centre providing a professional multidisciplinary pre-, peri- and postoperative care is crucial for patients with PH.

Future directions in the treatment of pulmonary hypertension

For many years, significant attention has been directed to the importance of exuberant pulmonary vasoconstriction and a deficit of pulmonary vasodilators in the development of PH. However, it is becoming increasingly accepted, that an integral aspect of the pathogenesis of PAH is an exuberant cellular proliferation leading to the obstruction of the precapillary pulmonary arterial bed. This recognition has refocused scientific attention on mechanisms by which this cellular proliferation and vascular remodelling occur. We like to highlight some of the systems currently addressed hereafter.

Cell proliferation and angiogenesis

The plexiform lesion typically found in patients with severe PAH is partially composed of disorganised proliferation of endothelial cells and smooth muscle cells [3, 32, 64]. These abnormal cells express markers of angiogenesis, such as vascular endothelial growth factor (VEGF) and demonstrate defects in growth suppressive genes, such as transforming growth factor- β (TGF- β). A significant percentage of cells within the plexiform lesions are monoclonal in origin, implying the proliferation of a single abnormal cell [65]. Heterozygous germline mutations in the gene encoding for bone morphogenetic protein receptor 2 (BMPR2) were independently reported by two groups [66, 67]. Ever since, mutations in the BMPR2 gene have been confirmed in about 60% of familial PAH and 5–25% in sporadic IPAH. BMPR2 is an ubiquitously expressed receptor for a family of secreted growth factors named bone morphogenetic proteins (BMPs), which themselves are members of the TGF- β superfamily. BMPs play a critical role in the mammalian development, but little is known about their role in adulthood [3]. Dysfunctional BMP signalling is thought to permit abnormal endothelial- and smooth muscle cell proliferation leading to PH [3]. The uncovering of the different mechanisms, by which these cellular and molecular changes result in a proliferating vascular phenotype and the development of therapeutic strategies addressing these pathologies is a current aim of many research groups. An other strategy is to look at medication known to alter cell proliferation and angiogenesis in other diseases, such as HMG-CoA reductase inhibitors or “statins”, which have been demonstrated to have anti-

proliferative and anti-inflammatory effects in addition to their cholesterol lowering effect [68]. Simvastatin has been tested in an open-label observational study of patients with PAH and was found to be safe and effective [69]. Furthermore, statins enhance BNPR2-expression and have also been reported to increase numbers of peripherally circulating endothelial precursor cells [70, 71]. Circulating endothelial precursor cells are considered as therapy in several ischaemic diseases, such as coronary heart or peripheral vascular disease [71]. Randomised controlled trial to address the efficacy of statins in PH are currently under way.

Serotonin or 5-hydroxytryptamine (5-HT) has been implicated in the pathogenesis of PAH [72, 73]. 5-HT levels are increased in the plasma of patients with idiopathic and anorexigen-associated PAH whereas platelet levels are low [74]. The mechanisms by which serotonin contributes to the development of PAH are still incompletely understood, however, recent experimental models suggest a role in both, vasoconstriction and cell proliferation [75, 76]. Serotonin reuptake inhibitors (SSRI) have been shown to reverse PH in rats and recently, a retrospective cohort study has shown a reduced mortality of patients under SSRI [77–79]. As SSRI's are well tolerated and widely used in patients with depression, the clinical investigation of the effect of SSRI's in PH seems reasonable. A randomised controlled pilot trial addressing this question is currently under way. Until the results of these or comparable further studies are available, no recommendation about SSRI's in PH can be provided.

Other promising antiproliferative agents currently debated are platelet derived growth factor (PDGF) inhibitors like STI571 (imatinib mesylate [Glivec[®]]). PDGF is a potent smooth muscle cell mitogen. The competitive inhibition of PDGF at its receptor through STI571 has been shown to reverse vascular proliferation [80]. One case report of a patient with severe, refractory PAH with a favourable response to imatinib has been published so far [81]. Despite this promising report, well designed randomised controlled trials to investigate the role of PDGF-inhibitors in the therapy of PAH are crucial before any therapeutic guidelines can be released.

Inflammation and immune response

PH is a frequent and potentially deadly complication of a heterogeneous assortment of systemic inflammatory and autoimmune con-

ditions, such as scleroderma, systemic lupus, mixed connective tissue disease and thyroiditis [3, 82]. A significant number of patients with IPAH have laboratory evidence of autoimmunity and inflammation [3, 83–86]. It is also well recognised, that patients with human immunodeficiency virus (HIV) infection are at risk for developing PH and that the presence of PAH significantly worsens survival in this patient population [87–89]. The mechanism by which HIV infection contributes to PH and why antiretroviral therapy improves PH in some patients are still unclear, the virus itself has never been located in the pulmonary vessels.

The putative role of inflammation and autoimmunity in the development of PAH raises the question about a beneficial effect of anti-inflammatory therapy. There exist numerous case reports of patients with PAH associated with connective tissue disease improving clinically and haemodynamically after immunosuppressive therapy [90–94]. However, there are no prospective cohort or randomised controlled studies published to date addressing the efficacy of immunosuppressive therapy in PAH. It is therefore difficult to make recommendations regarding the use of immunosuppressive therapy in the treatment of PAH. But most experts agree, that the associated condition in connective tissue disease associated PH should be addressed according to best clinical practice.

Conclusion

Diagnosis and treatment of PH have continuously and greatly improved in recent years. Multicentre randomised controlled trials have provided a basis for evidence based practice, but recommendations regarding therapy need to be applied in light of the individual patient situation and therefore, the importance of a thorough diagnostic evaluation, search for underlying causes and contributing factors cannot be overemphasised. Due to rapidly changing treatment options (including combination therapies) and the importance to include patients in well designed, randomised controlled trials, we strongly recommend to refer patients with PH to a specialised centre. The continued dedication and cooperation of basic scientists, clinical investigators and patient volunteers are required to ultimately triumph over this devastating disease.

References

- 1 Simonneau G, Galie N, Rubin LJ, et al. Clinical classification of pulmonary hypertension. *J Am Coll Cardiol.* 2004;43: 5–12S.
- 2 D'Alonzo GE, Barst RJ, Ayres SM, et al. Survival in patients with primary pulmonary hypertension. Results from a national prospective registry. *Ann Intern Med.* 1991;115:343–9.
- 3 Humbert M, Morrell NW, Archer SL, et al. Cellular and molecular pathobiology of pulmonary arterial hypertension. *J Am Coll Cardiol.* 2004;43:13–24S.
- 4 Rich S, Kaufmann E, Levy PS. The effect of high doses of calcium-channel blockers on survival in primary pulmonary hypertension. *N Engl J Med.* 1992;327:76–81.
- 5 Pengo V, Lensing AW, Prins MH, et al. Incidence of chronic thromboembolic pulmonary hypertension after pulmonary embolism. *N Engl J Med.* 2004;350:2257–64.
- 6 Fuster V, Steele PM, Edwards WD, Gersh BJ, McGoon MD, Frye RL. Primary pulmonary hypertension: natural history and the importance of thrombosis. *Circulation.* 1984;70: 580–7.
- 7 Bjornsson J, Edwards WD. Primary pulmonary hypertension: a histopathologic study of 80 cases. *Mayo Clin Proc.* 1985;60: 16–25.
- 8 Robbins IM, Kawut SM, Yung D, et al. A study of aspirin and clopidogrel in idiopathic pulmonary arterial hypertension. *Eur Respir J.* 2006;27:578–84.
- 9 Escudero J, Navarro J, Padua A, Betancourt L, Nava G. [Use of enalapril, an angiotensin-converting enzyme inhibitor, in pulmonary artery hypertension]. *Arch Inst Cardiol Mex.* 1986;56:467–73.
- 10 Rich S, Seidlitz M, Dodin E, et al. The short-term effects of digoxin in patients with right ventricular dysfunction from pulmonary hypertension. *Chest.* 1998;114:787–92.
- 11 Velez-Roa S, Ciarka A, Najem B, Vachiere JL, Naeije R and van de Borne P. Increased sympathetic nerve activity in pulmonary artery hypertension. *Circulation* 2004;110:1308–12.
- 12 Provencher S, Herve P, Jais X, et al. Deleterious effects of beta-blockers on exercise capacity and hemodynamics in patients with portopulmonary hypertension. *Gastroenterology.* 2006;130:120–6.
- 13 Doherty DE, Petty TL, Bailey W, et al. Recommendations of the 6th long-term oxygen therapy consensus conference. *Respir Care.* 2006;51:519–25.
- 14 Petty TL. Long-term outpatient oxygen therapy in advanced chronic obstructive pulmonary disease. *Chest.* 1980;77:304.
- 15 Petty TL, Nett LM. The history of long-term oxygen therapy. *Respir Care.* 1983;28:859–65.
- 16 Weitzenblum E, Sautegau A, Ehrhart M, Mammosser M, Pelletier A. Long-term oxygen therapy can reverse the progression of pulmonary hypertension in patients with chronic obstructive pulmonary disease. *Am Rev Respir Dis.* 1985;131:493–8.
- 17 Wuertemberger G, Zielinsky J, Sliwinsky P, Auw-Haedrich C, Matthys H. Survival in chronic obstructive pulmonary disease after diagnosis of pulmonary hypertension related to long-term oxygen therapy. *Lung.* 1990;168 Suppl:762–9.
- 18 Flenley DC, Muir AL. Cardiovascular effects of oxygen therapy for pulmonary arterial hypertension. *Clin Chest Med.* 1983;4:297–308.
- 19 Gluskowski J, Jedrzejska-Makowska M, Hawrylkiewicz I, Vertun B, Zielinski J. Effects of prolonged oxygen therapy on pulmonary hypertension and blood viscosity in patients with advanced cor pulmonale. *Respiration.* 1983;44:177–83.
- 20 Johansson BW, Torp A, Trelle E. Prolonged ambulatory oxygen therapy in pulmonary hypertension of various etiology. *Acta Med Scand.* 1971;189:155–9.
- 21 Roberts DH, Lepore JJ, Maroo A, Semigran MJ, Ginns LC. Oxygen therapy improves cardiac index and pulmonary vascular resistance in patients with pulmonary hypertension. *Chest.* 2001;120:1547–55.
- 22 O'Donohue WJ Jr. Home oxygen therapy. *Clin Chest Med.* 1997;18:535–45.

- 23 Sitbon O, Humbert M, Jais X, et al. Long-term response to calcium channel blockers in idiopathic pulmonary arterial hypertension. *Circulation*. 2005;111:3105–11.
- 24 Badesch DB, Abman SH, Ahearn GS, et al. Medical therapy for pulmonary arterial hypertension: ACCP evidence-based clinical practice guidelines. *Chest*. 2004;126:35–62S.
- 25 Barst RJ, Rubin LJ, Long WA, et al. A comparison of continuous intravenous epoprostenol (prostacyclin) with conventional therapy for primary pulmonary hypertension. The Primary Pulmonary Hypertension Study Group. *N Engl J Med*. 1996;334:296–302.
- 26 Badesch DB, Tapson VF, McGoon MD, et al. Continuous intravenous epoprostenol for pulmonary hypertension due to the scleroderma spectrum of disease. A randomized, controlled trial. *Ann Intern Med*. 2000;132:425–34.
- 27 Badesch DB, McLaughlin VV, Delcroix M, et al. Prostanoid therapy for pulmonary arterial hypertension. *J Am Coll Cardiol*. 2004;43:56–61S.
- 28 Simonneau G, Barst RJ, Galie N, et al. Continuous subcutaneous infusion of treprostinil, a prostacyclin analogue, in patients with pulmonary arterial hypertension: a double-blind, randomized, placebo-controlled trial. *Am J Respir Crit Care Med*. 2002;165:800–4.
- 29 Olschewski H, Ghofrani HA, Schmehl T, et al. Inhaled iloprost to treat severe pulmonary hypertension. An uncontrolled trial. German PPH Study Group. *Ann Intern Med*. 2000;132:435–43.
- 30 Olschewski H, Simonneau G, Galie N, et al. Inhaled iloprost for severe pulmonary hypertension. *N Engl J Med*. 2002;347:322–9.
- 31 Voelkel NF, Cool C. Pathology of pulmonary hypertension. *Cardiol Clin*. 2004;22:343–51.
- 32 Voelkel NF, Tuder RM. Cellular and molecular mechanisms in the pathogenesis of severe pulmonary hypertension. *Eur Respir J*. 1995;8:2129–38.
- 33 Channick R, Badesch DB, Tapson VF, et al. Effects of the dual endothelin receptor antagonist bosentan in patients with pulmonary hypertension: a placebo-controlled study. *J Heart Lung Transplant*. 2001;20:262–3.
- 34 Rubin LJ, Badesch DB, Barst RJ, et al. Bosentan therapy for pulmonary arterial hypertension. *N Engl J Med*. 2002;346:896–903.
- 35 Benigni A, Remuzzi G. Endothelin antagonists. *Lancet*. 1999;353:133–8.
- 36 Michelakis E, Tymchak W, Lien D, Webster L, Hashimoto K, Archer S. Oral sildenafil is an effective and specific pulmonary vasodilator in patients with pulmonary arterial hypertension: comparison with inhaled nitric oxide. *Circulation*. 2002;105:2398–403.
- 37 Zhao L, Mason NA, Morrell NW, et al. Sildenafil inhibits hypoxia-induced pulmonary hypertension. *Circulation*. 2001;104:424–8.
- 38 Ghofrani HA, Voswinkel R, Reichenberger F, et al. Differences in hemodynamic and oxygenation responses to three different phosphodiesterase-5 inhibitors in patients with pulmonary arterial hypertension: a randomized prospective study. *J Am Coll Cardiol*. 2004;44:1488–96.
- 39 Hoeper MM, Faulenbach C, Golpon H, Winkler J, Welte T, Niedermeyer J. Combination therapy with bosentan and sildenafil in idiopathic pulmonary arterial hypertension. *Eur Respir J*. 2004;24:1007–10.
- 40 Hoeper MM, Taha N, Bekjarova A, Gatzke R, Spiekerkoetter E. Bosentan treatment in patients with primary pulmonary hypertension receiving nonparenteral prostanoids. *Eur Respir J*. 2003;22:330–4.
- 41 Beyer S, Speich R, Fischler M, Maggiorini M, Ulrich S. Long-term experience with oral or inhaled vasodilator combination therapy in patients with pulmonary hypertension. *Swiss Med Wkly*. 2006;136:114–8.
- 42 Ghofrani HA, Rose F, Schermuly RT, et al. Oral sildenafil as long-term adjunct therapy to inhaled iloprost in severe pulmonary arterial hypertension. *J Am Coll Cardiol*. 2003;42:158–64.
- 43 Ghofrani HA, Wiedemann R, Rose F, et al. Combination therapy with oral sildenafil and inhaled iloprost for severe pulmonary hypertension. *Ann Intern Med*. 2002;136:515–22.
- 44 Humbert M, Barst RJ, Robbins IM, et al. Combination of bosentan with epoprostenol in pulmonary arterial hypertension: BREATHE-2. *Eur Respir J*. 2004;24:353–9.
- 45 Stiebellehner L, Petkov V, Vonbank K, et al. Long-term treatment with oral sildenafil in addition to continuous IV epoprostenol in patients with pulmonary arterial hypertension. *Chest*. 2003;123:1293–5.
- 46 Kataoka M, Satoh T, Manabe T, et al. Oral sildenafil improves primary pulmonary hypertension refractory to epoprostenol. *Circ J*. 2005;69:461–5.
- 47 Beattini C, Agnelli G, Pesavento R, et al. Incidence of chronic thromboembolic pulmonary hypertension after a first episode of pulmonary embolism. *Chest*. 2006;130:172–5.
- 48 Fedullo PF, Auger WR, Kerr KM, Rubin LJ. Chronic thromboembolic pulmonary hypertension. *N Engl J Med*. 2001;345:1465–72.
- 49 Hoeper MM, Mayer E, Simonneau G, Rubin LJ. Chronic thromboembolic pulmonary hypertension. *Circulation*. 2006;113:2011–20.
- 50 Jamieson SW, Kapelanski DP, Sakakibara N, et al. Pulmonary endarterectomy: experience and lessons learned in 1,500 cases. *Ann Thorac Surg*. 2003;76:1457–62; discussion 1462–4.
- 51 Moser KM, Auger WR, Fedullo PF. Chronic major-vessel thromboembolic pulmonary hypertension. *Circulation*. 1990;81:1735–43.
- 52 Klepetko W, Mayer E, Sandoval J, et al. Interventional and surgical modalities of treatment for pulmonary arterial hypertension. *J Am Coll Cardiol*. 2004;43:73–80S.
- 53 Dartevielle P, Fadel E, Mussot S, et al. Chronic thromboembolic pulmonary hypertension. *Eur Respir J*. 2004;23:637–48.
- 54 Bresser P, Fedullo PF, Auger WR, et al. Continuous intravenous epoprostenol for chronic thromboembolic pulmonary hypertension. *Eur Respir J*. 2004;23:595–600.
- 55 Kerr KM, Rubin LJ. Epoprostenol therapy as a bridge to pulmonary thromboendarterectomy for chronic thromboembolic pulmonary hypertension. *Chest*. 2003;123:319–20.
- 56 Nagaya N, Sasaki N, Ando M, et al. Prostacyclin therapy before pulmonary thromboendarterectomy in patients with chronic thromboembolic pulmonary hypertension. *Chest*. 2003;123:338–43.
- 57 Ghofrani HA, Schermuly RT, Rose F, et al. Sildenafil for long-term treatment of nonoperable chronic thromboembolic pulmonary hypertension. *Am J Respir Crit Care Med*. 2003;167:1139–41.
- 58 Hoeper MM, Kramm T, Wilkens H, et al. Bosentan therapy for inoperable chronic thromboembolic pulmonary hypertension. *Chest*. 2005;128:2363–7.
- 59 Bonderman D, Nowotny R, Skoro-Sajer N, et al. Bosentan therapy for inoperable chronic thromboembolic pulmonary hypertension. *Chest*. 2005;128:2599–603.
- 60 Feinstein JA, Goldhaber SZ, Lock JE, Ferndandes SM, Landzberg MJ. Balloon pulmonary angioplasty for treatment of chronic thromboembolic pulmonary hypertension. *Circulation*. 2001;103:10–3.
- 61 Pitton MB, Herber S, Mayer E, Thelen M. Pulmonary balloon angioplasty of chronic thromboembolic pulmonary hypertension (CTEPH) in surgically inaccessible cases. *Rof*. 2003;175:631–4.
- 62 International guidelines for the selection of lung transplant candidates. The American Society for Transplant Physicians (ASTP)/American Thoracic Society(ATS)/European Respiratory Society(ERS)/International Society for Heart and Lung Transplantation (ISHLT). *Am J Respir Crit Care Med*. 1998;158:335–9.
- 63 Mendeloff EN, Meyers BF, Sundt TM, et al. Lung transplantation for pulmonary vascular disease. *Ann Thorac Surg*. 2002;73:209–17; discussion 217–9.

- 64 Voelkel NF, Cool C, Taraceviene-Stewart L, et al. Janus face of vascular endothelial growth factor: the obligatory survival factor for lung vascular endothelium controls precapillary artery remodeling in severe pulmonary hypertension. *Crit Care Med.* 2002;30:S251-6.
- 65 Lee SD, Shroyer KR, Markham NE, Cool CD, Voelkel NF, Tudor RM. Monoclonal endothelial cell proliferation is present in primary but not secondary pulmonary hypertension. *J Clin Invest.* 1998;101:927-34.
- 66 Lane KB, Machado RD, Pauculo MW, et al. Heterozygous germline mutations in BMPR2, encoding a TGF-beta receptor, cause familial primary pulmonary hypertension. The International PPH Consortium. *Nat Genet.* 2000;26:81-4.
- 67 Deng Z, Morse JH, Slager SL, et al. Familial primary pulmonary hypertension (gene PPH1) is caused by mutations in the bone morphogenetic protein receptor-II gene. *Am J Hum Genet.* 2000;67:737-44.
- 68 Kwak B, Mulhaupt F, Myit S, Mach F. Statins as a newly recognized type of immunomodulator. *Nat Med.* 2000;6:1399-402.
- 69 Kao PN. Simvastatin treatment of pulmonary hypertension: an observational case series. *Chest.* 2005;127:1446-52.
- 70 Hu H, Sung A, Zhao G, et al. Simvastatin enhances bone morphogenetic protein receptor type II expression. *Biochem Biophys Res Commun* 2006;339:59-64.
- 71 Vasa M, Fichtlscherer S, Adler K, et al. Increase in circulating endothelial progenitor cells by statin therapy in patients with stable coronary artery disease. *Circulation.* 2001;103:2885-90.
- 72 MacLean MR. Pulmonary hypertension, anorexigens and 5-HT: pharmacological synergism in action? *Trends Pharmacol Sci.* 1999;20:490-5.
- 73 MacLean MR, Herve P, Eddahibi S, Adnot S. 5-hydroxytryptamine and the pulmonary circulation: receptors, transporters and relevance to pulmonary arterial hypertension. *Br J Pharmacol.* 2000;131:161-8.
- 74 Herve P, Launay JM, Scrobohaci ML, et al. Increased plasma serotonin in primary pulmonary hypertension. *Am J Med.* 1995;99:249-54.
- 75 Eddahibi S, Morrell N, d'Ortho MP, Naeije R, Adnot S. Pathobiology of pulmonary arterial hypertension. *Eur Respir J.* 2002;20:1559-72.
- 76 Eddahibi S, Raffestin B, Hamon M, Adnot S. Is the serotonin transporter involved in the pathogenesis of pulmonary hypertension? *J Lab Clin Med.* 2002;139:194-201.
- 77 Eddahibi S, Fabre V, Boni C, et al. Induction of serotonin transporter by hypoxia in pulmonary vascular smooth muscle cells. Relationship with the mitogenic action of serotonin. *Circ Res.* 1999;84:329-36.
- 78 Marcos E, Adnot S, Pham MH, et al. Serotonin transporter inhibitors protect against hypoxic pulmonary hypertension. *Am J Respir Crit Care Med.* 2003;168:487-93.
- 79 Kawut SM, Horn EM, Berekashvili KK, et al. Selective serotonin reuptake inhibitor use and outcomes in pulmonary arterial hypertension. *Pulm Pharmacol Ther.* 2006;19(5):370-4.
- 80 Schermuly RT, Dony E, Ghofrani HA, et al. Reversal of experimental pulmonary hypertension by PDGF inhibition. *J Clin Invest.* 2005;115:2811-21.
- 81 Ghofrani HA, Seeger W, Grimminger F. Imatinib for the treatment of pulmonary arterial hypertension. *N Engl J Med.* 2005;353:1412-3.
- 82 Simonneau G, Galiè N, Rubin LJ, et al. Clinical classification of pulmonary hypertension. *J Am Coll Cardiol.* 2004;43(12 Suppl.S):5-12S.
- 83 Voelkel NF, Cool C, Lee SD, Wright L, Geraci MW, Tudor RM. Primary pulmonary hypertension between inflammation and cancer. *Chest.* 1998;114:S225-30.
- 84 Dorfmueller P, Perros F, Balabanian K, Humbert M. Inflammation in pulmonary arterial hypertension. *Eur Respir J.* 2003;22:358-63.
- 85 Humbert M, Monti G, Brenot F, et al. Increased interleukin-1 and interleukin-6 serum concentrations in severe primary pulmonary hypertension. *Am J Respir Crit Care Med.* 1995;151:1628-31.
- 86 Nicolls MR, Taraseviene-Stewart L, Rai PR, Badesch DB, Voelkel NF. Autoimmunity and pulmonary hypertension: a perspective. *Eur Respir J.* 2005;26:1110-8.
- 87 Mehta NJ, Khan IA, Mehta RN, Sepkowitz DA. HIV-Related pulmonary hypertension: analytic review of 131 cases. *Chest.* 2000;118:1133-41.
- 88 Speich R, Jenni R, Opravil M, Pfaf M, Russi EW. Primary pulmonary hypertension in HIV infection. *Chest.* 1991;100:1268-71.
- 89 Zuber JP, Calmy A, Evison JM, et al. Pulmonary arterial hypertension related to HIV infection: improved hemodynamics and survival associated with antiretroviral therapy. *Clin Infect Dis.* 2004;38:1178-85.
- 90 Karmochkine M, Cacoub P, Dorent R, et al. High prevalence of antiphospholipid antibodies in precapillary pulmonary hypertension. *J Rheumatol.* 1996;23:286-90.
- 91 Morelli S, Giordano M, De Marzio P, Priori R, Sgreccia A, Valesini G. Pulmonary arterial hypertension responsive to immunosuppressive therapy in systemic lupus erythematosus. *Lupus.* 1993;2:367-9.
- 92 Groen H, Bootsma H, Postma DS, Kallenberg CG. Primary pulmonary hypertension in a patient with systemic lupus erythematosus: partial improvement with cyclophosphamide. *J Rheumatol.* 1993;20:1055-7.
- 93 Goupille P, Fauchier L, Babuty D, Fauchier JP, Valat JP. Precapillary pulmonary hypertension dramatically improved with high doses of corticosteroids during systemic lupus erythematosus. *J Rheumatol.* 1994;21:1976-7.
- 94 Dahl M, Chalmers A, Wade J, Calverley D, Munt B. Ten year survival of a patient with advanced pulmonary hypertension and mixed connective tissue disease treated with immunosuppressive therapy. *J Rheumatol.* 1992;19:1807-9.