

Bernhard Meier

Cardiovascular Department,
University Hospital,
Bern, Switzerland

Coronary stent fracture: problem or blessing?

Case report

A 57-year-old man underwent coronary angiography for angina and had a Cypher® stent (eluting sirolimus; Cordis Corporation, Miami, Florida USA) implanted into his tortuous right coronary artery (fig. 1A). The long stent straightened out the bends in the middle segment of the right coronary artery but created a kink at its proximal end (fig. 1B). The patient remained asymptomatic but had a follow-up coronary angiogram 20 months later because of palpitations (left ventricular bigeminus). The stent was found fractured in its mid-segment at the site of an initial bend of the coronary artery (fig. 1C). This fracture had relaxed the artery and the proximal kink had disappeared. Overall the artery had again a more natural appearance.

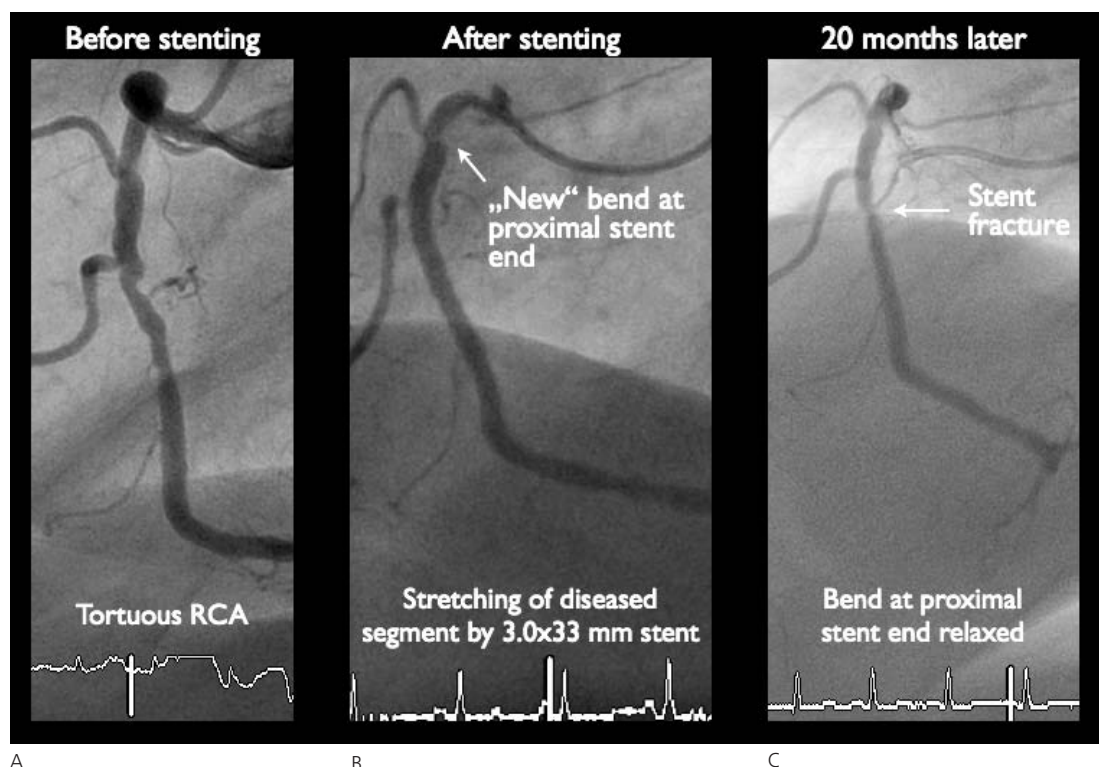
Stent fractures have been reported as rare complications. They are germane to long coronary stents that became more prevalent with the advent of drug-eluting stents curbing the fear of long in-stent restenosis. The topic has raised considerable interest in Asian countries [1] but is all but ignored in the rest of the world. Long stents impact unphysiological long straight segments on naturally tortuous coronary arteries engendering considerable strain and often kinks at both ends. A stent fracture may relax the strain on a coronary artery and thereby be more of a blessing than a problem.

Reference

- 1 Lee MS, Jurewitz D, Aragon J, Forrester J, Makkar RR, Kar S. Stent fracture associated with drug-eluting stents: clinical characteristics and implications. *Catheter Cardiovasc Interv.* 2007;69:387–94.

Figure 1

- A Right coronary artery before stenting.
- B Right coronary artery immediately after stenting.
- C Right coronary artery at follow-up.



There is no conflict of interest.

Correspondence:
Prof. Bernhard Meier, Cardiovascular Department
University Hospital Bern, CH-3010 Bern
E-Mail: bernhard.meier@insel.ch